

**Dario Paladini**

**CURRICULUM VITAE**

**Dario Paladini**  
**CURRICULUM VITAE**

- **Nome:** Dario Paladini;
- **Cittadinanza:** Italiana;
- **Data di nascita:** 17.4.1962;
- **Stato maritale:** Separato;
- **Lingue:** Italiano, Inglese, Spagnolo;
- **Posizione attuale:** Direttore Unità di Medicina e chirurgia Fetale – Ospedale IRCCS G.Gaslini di Genova

**Carriera:**

- **Luglio 1986:** **Laurea** - Università Federico II di Napoli (110/110 cum laude);
- **Luglio 1990:** **Specializzazione**, Dipartimento di Ginecologia Ostetricia - Università Federico II di Napoli (70/70);
- **Dicembre 1990:** **Collaboratore Tecnico** presso il Dipartimento di Ginecologia ed Ostetricia – Università Federico II di Napoli;
- **1994-2000:** **Funzionario tecnico** presso il Dipartimento di Ginecologia ed Ostetricia – Università Federico II di Napoli;
  - Responsabile Unità di Medicina e Cardiologia Fetale – Dipartimento di Ginecologia ed ostetricia - Università Federico II di Napoli;
  - Attività chirurgica in Oncologia Ginecologica
- **2001-2003:** **Ricercatore confermato** presso il Dipartimento di Ginecologia ed Ostetricia – Università Federico II di Napoli;
  - Responsabile Unità di Medicina e Cardiologia Fetale – Dipartimento di Ginecologia ed ostetricia - Università Federico II di Napoli;
  - Responsabile di Reparto;
  - Gruppo di Oncologia Ginecologica chirurgica: responsabile chirurgia tumori vulva e mammella;
- **2003-2013** **Professore Associato** presso il Dipartimento di Ginecologia ed Ostetricia – Università Federico II di Napoli;
  - Responsabile Unità di Medicina e Cardiologia Fetale;
  - Responsabile di reparto;
  - Gruppo di Oncologia Chirurgica Ginecologica; responsabile chirurgia tumori vulva e mammella;
- **Dal giugno 2013** **Direttore Unità Dipartimentale** di Medicina e chirurgia fetale – Ospedale IRCCS G.Gaslini, Genova;

## Titoli

- **1986, Luglio:** Laurea: 110/110 e lode;
- **1987, Luglio:** FMGEMS (Educational Committee for Foreign Medical Science);
- **1990, Giugno:** Specializzazione in Ginecologia ed Ostetricia: 70/70 cum laude;
- **1996, Aprile:** Diploma of Excellency in Obstetrics and Gynecology (E-EBGO);
- **1998, Aprile:** Diploma in Management Sanitario - Università Federico II

## Stages di specializzazione.

- **1985** (1 mese)
  - Dept. of General Surgery - **Guy's Hospital, London, UK** (Dir.: I McCall)
- **1988** (4 mesi)
  - Perinatal Cardiology Dept. - **Guy's Hospital, London, UK** (Dir.: Lindsay D. Allan)
- **1990-92** (24 mesi)
  - Divisione di Ginecologia Oncologica – **Istituto Tumori Milano** (Dir.: Prof.F.di Re)
- **1992** (6 mesi)
  - Gynaecologic Oncology Unit - **Queen Elizabeth Hospital, Newcastle, UK** (Dir.: Prof.John M. Monaghan)
- **1993-94** (18 mesi)
  - Divisione di Ginecologia Oncologica – **Istituto Tumori Milano** (Dir.: Prof.F.di Re)
- **1994-2001** (6 anni)
  - Unità di Medicina e Cardiologia Fetale – Dipart. Di Ginecologia ed Ostetricia– **Università Federico II of di Napoli** (Dir.: Prof.C.Nappi)
- **2006** (2 settimane)
  - Training avanzato in Lasercoagulazione per Trafusione Feto-Fetale
  - Unità di Medicina Fetale – Ospedale V.Buzzi, Milano (Dir.: Prof.U.Nicolini)
  - Unità di Medicina Fetale – Poissy University Hospital, Paris (Unità di Medicina Fetale: Prof.Y.Ville)

- **Società scientifiche.**

- Società Italiana di Ginecologia ed Ostetricia (**SIGO**)
- Società Italiana di Ecografia in Ostetricia e Ginecologia (**SIEOG**)
- Società Italiana di Oncologia Ginecologica (**SIOG**)
- International Society of Ultrasound in Obstetrics and Gynecology (**ISUOG**)
- International Gynaecologic Cancer Society (**IGCS**)
- American Institute for Ultrasound in Medicine (**AIUM**)
- Section Ecografica de la Sociedad Espanola de Ginecologia y Obstetricia (**SESEGO**)

### **Cariche societarie**

- **ISUOG**

- **2003-2011** Board Member
- **Dal 2004** Fetal Heart Task Force member
- **Dal 2005** Editorial Board member Ultrasound Obstet Gyecol
- **2005-2008** Education Committee Chair
- **Dal 2009** Education committee honorary member
- **Dal 2008** Clinical Standard Committee member
- **Dal 2010** Outreach committee member

- **SIEOG**

- **1993-94** Coordinatore Regionale
- **1995-97** Vice-Presidente
- **1999-00** Segretario
- **2001-02** Membro del direttivo
- **2003-04** Membro del direttivo
- **2007-08** Vice-Presidente
- **2010-13** Presidente
- **2013-** Past-President

- **SESEGO**

- **Dal 2005** Membro onorario

### **Revisore scientifico:**

- Am J Cardiology
- Brit J Obstet Gynecol
- Eur J Obstet Gynecol Reprod Biol
- Gynecologic Oncology
- Heart
- Obstetrics & Gynecology
- Obstetric Gynecologic Investigation
- Prenatal Diagnosis
- Ultrasound in Obstetrics & Gynecology

## Attività chirurgica:

### 1. Fino al 1990 (Specializzazione).

- a. *Primo Operatore*: taglio cesareo segmentario ed iterativo; isterectomia addominale semplice.
- b. *Primo Assistente*: isterectomia vaginale, uroginecologia, isterectomia postcesareo, miomectomia, metroplastica.

### 2. 1991-93 (Istituto Tumori Milano e Queen Elizabeth Hospital Gateshead, UK): totale interventi: 403.

- a. Ca Mammella (91):
  - i. Quadrantectomia + linfad.ascellare 63;
  - ii. Patey + linfad. ascellare 28;
  - iii. Resezione parziale 33.
  - iv. *Primo Operatore*:
    1. Quadrantectomia + linfad.ascellare 19;
    2. Patey + linfad. ascellare 8;
    3. Resezione parziale 3;
- b. Ca Ovaio (147): Staging ovarico\*§ 60;
  - i. Debulking\* 18;
  - ii. \*: interventi intestinali 20
  - iii. §: con linfad.lomboaortica e pelvica;
  - iv. Laparotomia esplorativa 69;
  - v. *Primo Operatore*:
    1. Laparotomia esplorativa + debulking 7;
- c. Ca Cervice (46):
  - i. Wertheim allargata 28;
  - ii. Wertheim con linfad. lomboaortica 11;
  - iii. Conizzazione 7;
  - iv. *Primo Operatore*:
    1. Wertheim allargata 3;
- d. Ca Vulva (52):
  - i. Vulvectomia rad. + linfad inguinale 34;
  - ii. Vulvect. rad. + linfad. inguinopelvica 4;
  - iii. Exeresi Laser 14;
  - iv. *Primo Operatore*:
    1. Vulvectomia rad. + linfad. inguinale 4;
- e. Altro (64):
  - i. Isterectomia semplice 35;
  - ii. Chirurgia ovarica conservativa 20;
  - iii. Isterectomia vag. laparoassistita 3;
  - iv. Chirurgia generale\* 9;
    1. \*: Splenectomia, nefrectomia,
    2. metastasectomia epatica,
    3. metastasectomia polmonare.

### 3. Dal 1994 (Università di Napoli).

In base ai trainings effettuati all'estero, il sottoscritto è stato prevalentemente coinvolto nella gestione della paziente oncologica (in particolare ca vulva e mammella) e di quella ostetrica a rischio elevato, meno nelle procedure chirurgiche di routine quali isteroannessectomia semplice etc. Anche nel campo ostetrico, il sottoscritto è stato da subito coinvolto, come Primo Aiuto di Guardia, responsabile di Reparto e Reperibile chirurgico nella gestione della paziente a rischio elevato. La casistica riportata di sotto rispecchia questo profilo.

#### a. Ginecologia Oncologica

##### i. *Primo Operatore:*

1. Vulvectomia rad. + linfad. inguinale	45
2. Quadrantectomia + dissezione ascellare	21
3. Mastectomia + dissezione ascellare	11
4. Staging carcinoma ovarico	9
5. Isterectomia radicale sec. Wertheim	11
6. Linfadenectomia pelvica sistematica	21

##### ii. *Primo Assistente:*

1. Isterectomia radicale	43
2. Staging carcinoma ovarico	34
3. Linfadenectomia pelvica sistematica	60

#### b. Chirurgia Ginecologica ed Ostetrica

##### i. *Primo Operatore:*

1. Isterectomia semplice extra-fasciale;	11
2. Miomectomia;	5
3. Ovariectomia;	15
4. Salpingectomia.	21
5. Taglio Cesareo d'elezione e d'urgenza;	201
6. Isterectomia post-cesareo (accreta/previa)	15
7. B-Lynch suture per atonia uterina	5
8. Legature arterie ipogastriche	11
9. Revisione cavitaria post-aborto	98
10. Laparotomia per gravidanza extrauterina	51

## **Esperienza in Medicina Fetale:**

- ❖ Responsabile, Centro regionale per diagnosi delle anomalie congenite
- ❖ Responsabile, Centro regionale per diagnosi delle cardiopatie congenite
- ❖ Counselling prenatale con le coppie.
- ❖ Lunga esperienza con ecografia di III livello e 3D
- ❖ Ecocardiografia fetale
- ❖ Diagnosi prenatale invasive (> 2000):
  - Amniocentesi
  - Villocentesi
  - Cordocentesi
- ❖ Terapie fetali invasive (circa 100):
  - Posizionamento di shunt thoraco-amniotic
  - Transfusioni in utero
  - Lasercoagulazione anastomosi placentari per TTTS
  - Cord-clamping

## **Insegnamenti accademici:**

- Corso ufficiale per la laurea in Medicina e Chirurgia;
- Corso ufficiale di Oncologia Ginecologia per Diploma Ostetrica;
- Corso ufficiale di Ecografia ostetrico-ginecologica ed ecocardiografia fetale in Specializzazione;
- Lezioni corso ufficiale per Dottorato di Ricerca (seminari e training)
- Corsi di training teorico e pratico in Italia ed all'estero, in tutto il mondo, con la SIEOG e l'ISUOG, società italiana e mondiale, rispettivamente, per l'ecografia ostetrico-ginecologica

## **Collaborazioni scientifiche internazionali**

- Centro afferente alle varie fasi degli studi del **gruppo IOTA** (International Ovarian Tumor Analysis) group, come risulta da più di 10 pubblicazioni del gruppo multicentrico sulla predittività ecografica del carcinoma ovarico (vedi sezione finale pubblicazioni)
- **Fetal Heart ISUOG Task Force** sulle Linee Guida per la valutazione del Cuore Fetale, con pubblicazione di Linee Guida internazionali su Screening cardiaco ed Ecocardiografia fetale
- **ISUOG Clinical Standard Committee**, per la verifica e la pubblicazione di Linee Guida internazionali su ecografia ostetrico-ginecologica

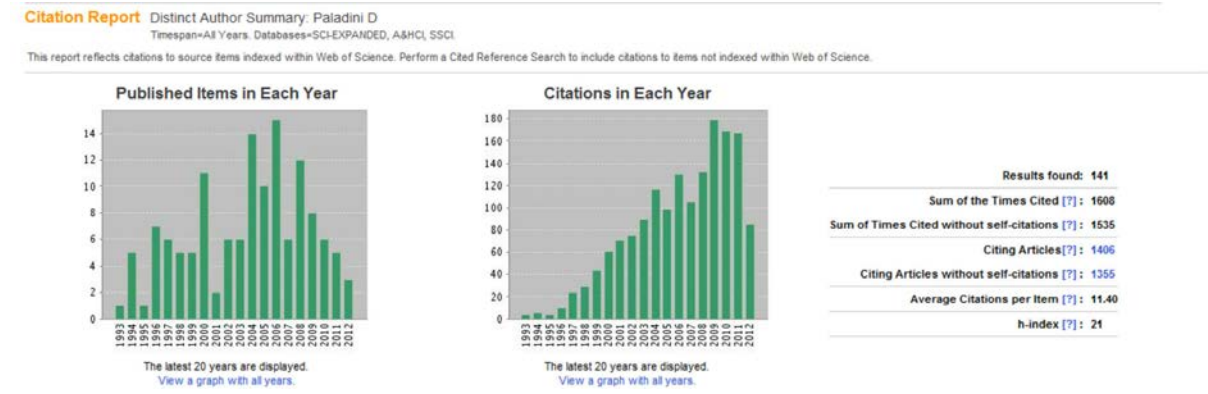
## **Testi e manuali:**

- 1) **LE CARDIOPATIE CONGENITE IN UTERO.** Ianniruberto A, *Paladini D*  
CIC Edizioni, Roma 1996.
- 2) **VIDEOATLANTE DI CARDIOLOGIA FETALE.** *Paladini D, Marasini M, Volpe P.*  
Editors. I Messaggi Editore, Bari, 2001.
- 3) **ECOGRAFIA IN OSTETRICIA.** Iaccarino M, *Paladini D, Ventruto V.* Verduci Editore,  
2002
- 4) **ANOMALIE FETALI IN UTERO.** *Paladini D, Volpe P.* Editors, 2004, 2010
- 5) **MANUALE DI OSTETRICIA E GINECOLOGIA,** *C.Nappi.* Capitolo su “Carcinoma della Vulva”
- 6) **ULTRASOUND OF FETAL ANOMALIES** *Paladini D, Volpe P, Informa, 2007.*
- 7) **MANUALE DI OSTETRICIA E GINECOLOGIA,** *C. Zanoio,* Capitolo su “La mammella: lesioni benigne e maligne”
- 8) **OBSTETRIC ULTRASOUND** *Fleisher A, Romero R editors.* Capitoli: “Color Doppler in obstetrics” e “Anomalie del tratto gastro-intestinale”
- 9) **TWINING'S ULTRASOUND OF FETAL ANOMALIES** *Peter Twining editor.* Capitolo su: “Spinal anomalies”, *in press*

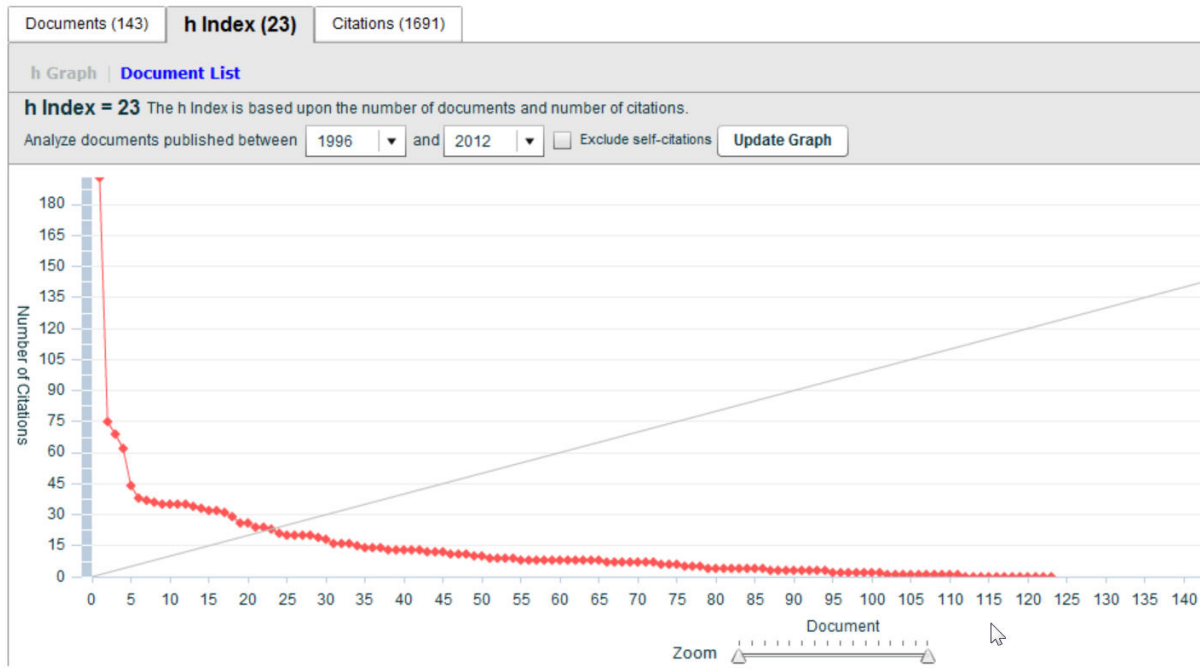


# H index

H Index secondo Web of Knowledge: 20



H Index secondo Scopus: 23



**Articoli pubblicati su riviste in inglese ad Impact Factor  
(Impact Factor 375 ca – 64/126 articoli a primo nome)**

Journal	Impact Factor	#
• Am J Cardiol	3.7	1
• Am J Med Genet	2.5	1
• Am J Obstet Gynecol	3.3	2
• Ann Surg Oncol	4.2	1
• Arch Dis Child	2.6	1
• Birth Defects Res A Clin Mol Terat	2.5	1
• Br J Clin Pharmacol	3.1	1
• Cancer	5.1	2
• Clin Chem Lab Med	2.1	1
• Clin Chim Acta	2.6	1
• Clin Dysmorph	0.6	1
• Clin Exper Hypert Pregn	1.4	1
• Clinic Exp Obstet Gynecol	0.4	1
• Cytometry	3.8	1
• Eur J Echocardiogr	2.1	1
• Eur J Gynecol Oncol	0.6	2
• Eur J Obstet Gyecol Reprod Biol	1.8	4
• Fertil Steril	4.0	1
• Gut	10.6	1
• Gynecol Oncol	3.8	2
• Haematologica	6.5	2
• Heart	4.7	2
• J Am Coll Surg	4.2	1
• J Cardiovasc Med	0.8	3
• J Endocrinol Invest	1.5	1
• J Perin Med	1.9	1
• J Ultrasound Med	1.3	3
• Int J Gynecol Cancer	1.6	3
• Ital Heart J	0.8	1
• Neuropediatrics	1.0	1
• Obstet Gynecol	4.4	5
• Prenatal Diagn	2.2	13
• Texas Heart Inst J	0.7	1
• Thrombosis Haemostasis	4.7	3
• Ultrasound Obstet Gynecol	3.2	58

Sommario per rivista e relativo Impact Factor

## Articoli (totale 126)

- 1) Di Meglio A, Esposito A, *Paladini D*, Castaldi L, Di Meglio G, Di Pietto L. Integrated diagnostic techniques in the identification of ovarian malignancies. *European Journal of Gynecologic Oncology* 1988; 9(3):257.
- 2) Di Meglio A, Di Meglio G, Esposito A, *Paladini D*, Castaldi L, Ferrandino F. Echopatterns of the ovarian dermoid tumor. *European Journal of Gynecologic Oncology* 1988; 9(3):242.
- 3) Di Lieto A, Campanile M, *Paladini D*, Albano G, Paladini A. Atrial natriuretic peptide and the renin-angiotensin-aldosterone system in normotensive and hypertensive pregnancy. *Clinical and Experimental Hypertension in Pregnancy* 1988;B7(1&2):89.
- 4) Martinelli P, *Paladini D*, Nicotra A, Guerritore T. In utero diagnosis of oropharyngeal teratoma. A case report. *European Journal of Obstetrics, Gynecology and Reproductive Biology* 1990; 35:291.
- 5) Martinelli P, *Paladini D*, Nicotra A, Russo R, D'Armiento MR. Holocardius: antenatal diagnosis and pathogenetic evaluation. *European Journal of Obstetrics, Gynecology and Reproductive Biology* 1990; 36:153.
- 6) *Paladini D*, Chita S, Allan LD. Prenatal measurement of cardio-thoracic ratio in evaluation of heart disease. *Archives of Disease in Childhood* 1990; 65:20.
- 7) *Paladini D*, Di Meglio A, Esposito A, Di Meglio G, Riccio A. Ultrasonic features of an ovarian cystohemangioma. *European Journal of Obstetrics, Gynecology and Reproductive Biology* 1991; 40:239.
- 8) Fontanelli R, *Paladini D*, Raspagliesi F. The role of appendectomy in staging procedures for ovarian cancer. *Gynecologic Oncology* 1992; 46:42-44.
- 9) *Paladini D*, Calabro' R, Palmieri S, D'Andrea T. Prenatal diagnosis of congenital heart disease and fetal karyotyping. *Obstetrics & Gynecology* 1993; 81:679-82.
- 10) Pacileo G, *Paladini D*, Pisacane C, Palmieri S, Russo MG, Calabrò R. Role of changing loading conditions on atrio-ventricular flow velocity patterns in normal human fetuses. *Am J Cardiol* 1994; 73:991-3.
- 11) di Re F, *Paladini D*, Fontanelli R, Feudale A, Raspagliesi F. Surgical staging for epithelial ovarian tumors of low malignant potential. *Int J Gynecol Cancer* 1994; 4:310-14.
- 12) *Paladini D*, Fontanelli R, Raspagliesi F, Ntousias V. Intestinal operations during surgical procedures for epithelial ovarian cancer. *Int J Gynecol Cancer* 1994; 4:320-23.
- 13) Pacileo G, *Paladini D*, Palmieri S, Pisacane C, Russo MG, Calabrò R. Echocardiographic assessment of diastolic function in normal human fetuses. *J Perinat Med* 1994; 22 (Suppl.1):43-45.

- 14) *Paladini D*, Cross P, Lopes A, Monaghan JM. Prognostic significance of lymph-node variables in squamous cell carcinoma of the vulva. *Cancer* 1994; 74:2491-96.
- 15) *Paladini D*, Raspagliesi F, Fontanelli R, Ntousias V. Radical surgery after induction chemotherapy in locally advanced cervical cancer. A feasibility study. *Int J Gynecol Cancer* 1995; 5:296-300.
- 16) *Paladini D*, Palmieri S, Russo MG, Pacileo G. Cardiac multiple rhabdomyomatosis. Prenatal diagnosis and natural history. *Ultrasound Obstet Gynecol* 1995; 7(1):137-8.
- 17) *Paladini D*, Palmieri S, Morelli PM, Forleo F, Morra T, Salviati M, Zampella C, D'Angelo A, Martinelli P. Fetal inguino-scrotal hernia: prenatal ultrasound diagnosis and pathogenetic evaluation. *Ultrasound Obstet Gynecol* 1996; 7(2):145-6.
- 18) *Paladini D*, Palmieri S, Lecora M, Perone L, Di Meglio A, D'Armiento MR, Cascioli C, Martinelli P. Prenatal ultrasound diagnosis of Roberts syndrome in a family with negative history. *Ultrasound Obstet Gynecol* 1995; 7:208-10.
- 19) Lupi G, Raspagliesi F, Zucali R, Fontanelli R, *Paladini D*, Kenda R, di Re F. Combined pre-operative chemo-radiotherapy followed by radical surgery in locally advanced vulvar carcinoma. A pilot study. *Cancer* 1996; 77:1472-8.
- 20) *Paladini D*, Palmieri S, D'Angelo A, Martinelli P. Prenatal ultrasound diagnosis of cerebral artero-venous fistola. *Obstet Gynecol* 1996; 88:34-6.
- 21) *Paladini D*, Rustico MA, Todros T, Palmieri S, Gaglioti P, Benetton A. Conotruncal anomalies in prenatal life. *Ultrasound Obstet Gynecol* 1996; 8:241-6.
- 22) *Paladini D*, Russo MG, Palmieri S, et al. Myocardial displasia in a 3<sup>RD</sup> trimester fetus. *Texas Heart Inst J* 1997; 24:53-7.
- 23) Grandone E, Margaglione M, Colaizzao D, Cappucci G, *Paladini D*, et al. Factor V Leiden, C>T MTHFR polymorphism and genetic susceptibility to preeclampsia. *Thrombosis & Haemostasis* 1997; 77:1052-4.
- 24) Martinelli P, *Paladini D*, D'Armiento MR, Scarano G. Prenatal diagnosis of cloverleaf skull in the subtype 2 Pfeiffer syndrome. Letter to the editor. *Clinical Dysmorphol* 1997; 6:89-90.
- 25) *Paladini D*, Palmieri S, Celentano E, et al. Pulmonary venous blood flow in the human fetus. *Ultrasound in Obstet Gynecol* 1997; 10:1-5.
- 26) Raspagliesi F, Fontanelli R, *Paladini D*, di Re E. Conservative surgery in "high risk" epithelial ovarian carcinoma. *J Am Coll Surgeons* 1997; 185:457-60.
- 27) *Paladini D*, Pacileo G, Palmieri S, et al. Prenatal diagnosis of 22q11 microdeletion in a fetus with a conotruncal heart defect. *Ultrasound in Obstet & Gynecol* 1998; 11:68-70.

- 28) *Paladini D, Morra T, Guida F, et al.* Prenatal diagnosis and perinatal management of a lingual lymphangioma. *Ultrasound in Obstet & Gynecol* 1998; 11:141-3.
- 29) *Paladini D, Morra T, Teodoro A, et al.* Prenatal diagnosis and hemodynamic evaluation of Klippel-Trenaunay-Weber syndrome. *Ultrasound in Obstet & Gynecol* 1998; 11:215-17.
- 30) *Paladini D, Russo MG, Palmieri S, et al.* Prenatal diagnosis of aortic insufficiency. *Ultrasound in Obstet & Gynecol* 1998; 11:355-57.
- 31) *Paladini D, Morra T, Teodoro A, et al.* Prenatal diagnosis of micrognathia in the fetus. The jaw index. *Obstet Gynecol* 1999; 93:382-6.
- 32) *Paladini D, D'Agostino A, Liguori M, et al.* Prenatal findings in trisomy 16q. *Pren Diagnosis* 1999; 19:472-5.
- 33) Grandone E, Margaglione M, Colaizzo D, Cappucci G, Sciannammè, Mantanaro S, *Paladini D, Martinelli P, Di Minno G.* Prothrombotic genetic risk factors and the occurrence of gestational hypertension with or without proteinuria. *Thromb Haemost* 1999; 81: 349-52.
- 34) *Paladini D.* Prenatal screening of congenital heart disease between ethics and cost-effectiveness. Time for a change in current prenatal ultrasound screening policies?- *Editorial Ultrasound Obstet Gynecol* 1999; 14: 225-8.
- 35) *Paladini D, Tartaglione A, Agangi A, et al.* The association between congenital heart disease and Down syndrome in prenatal life. *Ultrasound Obstet Gynecol* 2000; 15: 104-8.
- 36) *Paladini D, D'Armiento M, Ardovino I, Martinelli P.* Prenatal diagnosis of the cerebro-oculo-facio-skeletal (COFS) syndrome. *Ultrasound Obstet Gynecol* 2000; 16: 91-3.
- 37) *Paladini D, Lamberti A, Agangi A, Martinelli P.* Cleido-cranial dysostosis. Prenatal diagnosis of a late onset form. *Ultrasound Obstet Gynecol* 2000; 16: 100-1.
- 38) Castaldo G, Martinelli P, Massa C, Fuccio A, Grosso M, Rippa E, *Paladini D, Salvatore F.* Prenatal diagnosis of cystic fibrosis: a case of twin pregnancy diagnosis and a review of 5 years' experience. *Clin Chim Acta* 2000; 298:121-33.
- 39) *Paladini D, Borghese A, Arienzo M, Teodoro A, Martinelli P, Nappi C.* Prospective ultrasound diagnosis of Pallister-Killian syndrome in the second trimester of pregnancy: the importance of the facial fetal profile. *Prenat Diagnosis* 2000; 20:996-8.
- 40) *Paladini D, Palmieri S, Lamberti A, Teodoro A, Martinelli P, Nappi C.* Characterization and natural history of ventricular septal defects in the fetus. *Ultrasound Obstet Gynecol.* 2000 Aug;16(2):118-22. PubMed PMID: 11117079.
- 41) Pacileo G, *Paladini D, Russo MG, Pisacane C, Santoro G, Calabro R.* Echocardiographic assessment of ventricular filling pressure during the second and third trimester of gestation. *Ultrasound Obstet Gynecol* 2000; 16:128-32.

- 42) Monni G, *Paladini D*, Ibba RM, Teodoro A, Zoppi MA, Lamberti A, Floris M, Putzolu, M, Martinelli P. Prenatal ultrasound diagnosis of congenital cystic adenomatoid malformation of the lung: a report of 26 cases and review of the literature. *Ultrasound Obstet Gynecol* 2000; 16:159-62.
- 43) Raspagliesi F, Ditto A, *Paladini D*, Fontanelli R, Stefanon B, Dipalma S, De Palo G. Prognostic indicators in melanoma of the vulva. *Ann Surg Oncol* 2000; 7:738-42.
- 44) *Paladini D*, Lamberti A, Teodoro A, Arienzo M, Tartaglione A, Martinelli P. Tissue Doppler imaging of the fetal heart. *Ultrasound Obstet Gynecol* 2000; Nov:530-5.
- 45) *Paladini D*, Tartaglione A, Agangi A, Foglia S, Martinelli P, Nappi C. Pena-Shokeir phenotype with variable onset in three consecutive pregnancies. *Ultrasound Obstet Gynecol* 2001; 17:163-5.
- 46) Grandone E, Margaglione M, Colaizzo D, Pavone G, *Paladini D*, Martinelli P, Di Minno G. Lower birth weight in neonates of mothers carrying factor V G1691A and factor II. *Haematologica* 2002 Feb; 87(2):177-81.
- 47) Martinelli P, Grandone E, Colaizzo D, *Paladini D*, Sciannone N, Margaglione M, Di Minno G. Familial thrombophilia and the occurrence of fetal growth restriction. *Haematologica* 2001; 86:428-31.
- 48) Martinelli P, Russo R, Agangi A, *Paladini D*. Prenatal ultrasound diagnosis of frontonasal dysplasia. *Prenat Diagn* 2002; 22:375-9.
- 49) *Paladini D*, Russo MG, Vassallo M, Tartaglione A, Pacileo G, Martinelli P, Calabro R. Ultrasound evaluation of aortic valve anatomy in the fetus. *Ultrasound Obstet Gynecol* 2002; 20:30-4.
- 50) *Paladini D*, Russo M, Teodoro A, Pacileo G, Capozzi G, Martinelli P, Nappi C, Calabro R. Prenatal diagnosis of congenital heart disease in the Naples area during the years 1994-1999 – The experience of a joint fetal-pediatric cardiology unit. *Prenat Diagn* 2002 Jul; 22(7):545-52.
- 51) *Paladini D*, Russo MG, Tartaglione A, Loffredo A, Martinelli P. Prenatal ultrasound diagnosis of Toriello-Carey syndrome. *Prenat. Diagn.* 2002 Dec; 22(13):1185-87.
- 52) *Paladini D*, Tartaglione A, Lamberti A, Lapadula C, Martinelli P. Prenatal ultrasound diagnosis of Nager syndrome. *Ultrasound Obstet Gynecol.* 2003 Feb; 21(2):195-7.
- 53) Todros T, *Paladini D*, Chiappa E, Russo MG, Gaglioti P, Pacileo G, Cau MA, Martinelli P. Pulmonary stenosis and atresia with intact ventricular septum during prenatal life. *Ultrasound Obstet Gynecol.* 2003 Mar; 21(3):228-33.
- 54) *Paladini D*, Tartaglione A, Vassallo M, Martinelli P. Prenatal ultrasonographic findings of a cardiac myxoma. *Obstet Gynecol* 2003 Nov; 102(5 Pt2):1174-6.

- 55) Volpe P, *Paladini D*, Marasini M, Buonadonna AL, Russo MG, Caruso G, Marzullo G, Vassallo M, Martinelli P, Gentile M. Common arterial trunk in the fetus: characteristics, associations, and outcome in a multicenter series of 23 cases. *Heart* 2003 Dec; 89(12):1437-41.
- 56) Greco L, Veneziano A, Di Donato L, Zampella C, Pecoraro M, *Paladini D*, Paparo F, Vollaro A, Martinelli P. Undiagnosed coeliac disease does not appear to be associated with unfavourable outcome of pregnancy. *Gut* 2004 Jan; 53(1):149-51.
- 57) *Paladini D*, Russo MG, Vassallo M, Tartaglione A. The “in-plane” view of the inter-ventricular septum. A new approach to the characterization of ventricular septal defects in the fetus. *Prenat. Diagn.* 2003 Dec 30;23(13):1052-5.
- 58) Chiaffarino F, Parazzini F, *Paladini D*, Acaia B, Ossola W, Marozio L, Facchinetti F, Del Giudice A. A small randomised trial of low-dose aspirin in women at high risk of pre-eclampsia. *Eur J Obstet Gynecol Reprod Biol* 2004 Feb 10; 112(2):142-4.
- 59) Maruotti GM, *Paladini D*, Aganti A, Martinelli P. Prospective prenatal diagnosis of Fraser syndrome variant in a family with negative history. *Prenat. Diagn.* 2004 Jan; 24(1):69-70.
- 60) *Paladini D*, Vassallo M, Tartaglione A, Lapadula C, Martinelli P. The role of tissue harmonic imaging in fetal echocardiography. *Ultrasound Obstet Gynecol* 2004 Feb; 23(2):159-64.
- 61) *Paladini D*, Vassallo M, D’Armiento MR, Cianciaruso B, Martinelli P. Prenatal detection of multiple fetal anomalies following inadvertent exposition to cyclophosphamide in the first trimester of pregnancy. *Birth Defects Res A Clin Mol Teratol* 2004 Feb; 70(2):99-100.
- 62) *Paladini D*, Foglia S, Sglavo G, Martinelli P. Congenital constriction band of the upper arm: the role of three-dimensional ultrasound in diagnosis, counseling and multidisciplinary consultation. *Ultrasound Obstet Gynecol* 2004 May; 23(5):520-2.
- 63) Martinelli P, Maruotti GM, Pasquali D, *Paladini D*, Aganti A, Ripa E, Colantuoni V, Bellastella A, Sinisi AA. Genetic prenatal RET testing and pregnancy management of multiple endocrine neoplasia Type II A (MEN2A): a case report. *J Endocrinol Invest* 2004 Apr; 27(4):357-60.
- 64) Martinelli P, Maruotti GM, Agangi A, Mazzarelli LL, Bifulco G, *Paladini D*. Prenatal diagnosis of hemifacial microsomia and ipsilateral cerebellar hypoplasia in a fetus with oculoauriculovertebral spectrum. *Ultrasound Obstet Gynecol* 2004 Aug; 24(2):199-201.
- 65) Volpe P, *Paladini D*, Marasini M, Buonadonna AL, Russo MG, Caruso G, Marzullo A, Arciprete P, Martinelli P, Gentile M. Characteristics, associations and outcome of absent pulmonary valve syndrome in the fetus. *Ultrasound Obstet Gynecol* 2004 Nov; 24(6):623-8.
- 66) *Paladini D*, Volpe P, Russo MG, Vassallo M, Sglavo G, Gentile M. Aortic coarctation: prognostic indicators of survival in the fetus. *Heart* 2004 Nov; 90(11):1348-9.

- 67) *Paladini D, D'Armiento MR, Martinelli P.* Prenatal ultrasound diagnosis of poland syndrome. *Obstet Gynecol* 2004 Nov; 104(5 Pt 2):1156-9;
- 68) Martinelli P, Martinelli V, Agangi A, Maruotti GM, *Paladini D*, Ciancia R, Rotoli B. Interferon alfa treatment for pregnant women affected by essential thrombocythemia: case reports and a review. *Am J Obstet Gynecol* 2004 Dec; 191(6):2016-20.
- 69) Falcidia E, Parano E, Grillo A, Pavone P, Takabayashi H, Trifiletti RR, Scollo P, Dallapiccola B, Grammatico P, Novelli A, *Paladini D*, Monni G, Gulisano A, Scassellati G. Fetal Cells in Maternal Blood: A Six-Fold Increase in Women who have Undergone Amniocentesis and Carry a Fetus with Down Syndrome: A Multicenter Study. *Neuropediatrics* 2004 Dec; 35(6):321-4.
- 70) Genesio R, De Brasi D, Conti A, Borghese A, Di Micco P, Di Costanzo P, *Paladini D*, Ungaro P, Nitsch L. Inverted duplication of 15q with terminal deletion in a multiple malformed newborn with intrauterine growth failure and lethal phenotype. *Am J Med Genet A.* 2004 Aug 1;128(4):422-8. Erratum in: *Am J Med Genet A.* 2005 Jul 1;136(1):113.
- 71) Romeo E, D'Alto M, Russo MG, Sarubbi B, Cardaropoli D, *Paladini D*, Pacileo G, Annunziata A, Calabro R. Fetal supraventricular tachycardia diagnosed and treated at twenty-four weeks of gestation and after birth: a case report. *Ital Heart J.* 2004 Oct;5(10):777-80.
- 72) Agangi A, *Paladini D*, Bagolan P, Maruotti GM, Martinelli P. Split notochord syndrome variant: prenatal findings and neonatal management. *Prenat Diagn.* 2005 Jan;25(1):23-7. Review.
- 73) *Paladini D*, Marasini M, Volpe P. Severe ductal constriction in the third-trimester fetus following maternal self-medication with nimesulide. *Ultrasound Obstet Gynecol.* 2005 Apr;25(4):357-61.
- 74) *Paladini D*, Vassallo M, Sglavo G, Russo MG, Martinelli P. Diagnosis and outcome of congenital heart disease in fetuses from multiple pregnancies. *Prenat Diagn.* 2005 May;25(5):403-6.
- 75) *Paladini D*, Caruso G, Sglavo G, Lapadula C, Parisi G, Martinelli P. Hypoplastic left heart syndrome associated with left ventricle-coronary artery-pulmonary artery fistula: prenatal diagnosis and histological correlation. *Ultrasound Obstet Gynecol.* 2005 Jul;26(1):78-80.
- 76) *Paladini D*, Rustico M, Viora E, Giani U, Bruzzese D, Campogrande M, Martinelli P. Fetal size charts for the Italian population. Normative curves of head, abdomen and long bones. *Prenat Diagn.* 2005 Jun;25(6):456-64.
- 77) *Paladini D*, Vassallo M, Sglavo G, Lapadula C, Longo M, Nappi C. Cavernous lymphangioma of the face and neck: prenatal diagnosis by three-dimensional ultrasound. *Ultrasound Obstet Gynecol.* 2005 Sep;26(3):300-2.



- 78) Di Salvo G, Russo MG, *Paladini D*, Pacileo G, Felicetti M, Ricci C, Cardaropoli D, Palma M, Caso P, Calabro R. Quantification of regional left and right ventricular longitudinal function in 75 normal fetuses using ultrasound-based strain rate and strain imaging. *Ultrasound Med Biol*. 2005 Sep;31(9):1159-62.
- 79) *Paladini D*, Sglavo G, Quarantelli M, D'armiento MR, Martinelli P, Salvatore M. Large infratentorial subdural hemorrhage diagnosed by ultrasound and MRI in a second-trimester fetus. *Ultrasound Obstet Gynecol*. 2005 Dec;26(7):789-91; discussion 791.
- 80) Grandone E, Corrao AM, Colaizzo D, Vecchione G, Di Girgenti C, *Paladini D*, Sardella L, Pellegrino M, Zelante L, Martinelli P, Margaglione M. Homocysteine metabolism in families from southern Italy with neural tube defects: role of genetic and nutritional determinants. *Prenat Diagn*. 2006 Jan;26(1):1-5.
- 81) Maruotti GM, Agangi A, Martinelli P, *Paladini D*. Early prenatal diagnosis of concordant posterior urethral valves in male monozygotic twins. *Prenat Diagn*. 2006 Jan;26(1):67-70.
- 82) Valentin L, Ameye L, Testa A, Lecuru F, Bernard JP, *Paladini D*, Van Huffel S, Timmerman D. Ultrasound characteristics of different types of adnexal malignancies. *Gynecol Oncol*. 2006 Jul;102(1):41-8.
- 83) *Paladini D*, Volpe P, Marasini M, Russo MG, Vassallo M, Gentile M, Calabro R. Diagnosis, characterization and outcome of congenitally corrected transposition of the great arteries in the fetus: a multicenter series of 30 cases. *Ultrasound Obstet Gynecol*. 2006 Mar;27(3):281-5.
- 84) Todros T, Verdiglione P, Ogge G, *Paladini D*, Vergani P, Cardaropoli S. Low incidence of hypertensive disorders of pregnancy in women treated with spiramycin for toxoplasma infection. *Br J Clin Pharmacol*. 2006 Mar;61(3):336-40.
- 85) Vassallo M, Pascotto M, Pisacane C, Santoro G, *Paladini D*, Russo MG, Calabro R. Right superior vena cava draining into the left atrium: prenatal diagnosis and postnatal management. *Ultrasound Obstet Gynecol*. 2006 Apr; 27(4):445-8.
- 86) *Paladini D*, Volpe P. Posterior fossa and vermian morphometry in the characterization of fetal cerebellar abnormalities: a prospective three-dimensional ultrasound study. *Ultrasound Obstet Gynecol*. 2006 May;27(5):482-9.
- 87) *Paladini D*, Vassallo M, Sglavo G, Lapadula C, Martinelli P. The role of spatio-temporal image correlation (STIC) with tomographic ultrasound imaging (TUI) in the sequential analysis of fetal congenital heart disease. *Ultrasound Obstet Gynecol*. 2006 May;27(5):555-61.
- 88) Volpe P, *Paladini D*, Resta M, Stanziano A, Salvatore M, Quarantelli M, De Robertis V, Buonadonna AL, Caruso G, Gentile M. Characteristics, associations and outcome of partial agenesis of the corpus callosum in the fetus. *Ultrasound Obstet Gynecol*. 2006 May;27(5):509-16.

- 89) Cardaropoli D, Russo MG, *Paladini D*, Pisacane C, Caputo S, Giliberti P, Calabro R. Prenatal echocardiography in a case of Uhl's anomaly. *Ultrasound Obstet Gynecol*. 2006 Jun;27(6):713-4.
- 90) Martinelli P, Maruotti GM, Coppola A, Agangi A, *Paladini D*, Grandone E, Di Minno G. Pregnancy in a woman with a history of Budd-Chiari syndrome treated by porto-systemic shunt, protein C deficiency and bicornuate uterus. *Thromb Haemost*. 2006 Jun;95(6):1033-4.
- 91) Fortunato G, Carandente Giarrusso P, Martinelli P, Sglavo G, Vassallo M, Tomeo L, Rea M, *Paladini D*. Cardiac troponin T and amino-terminal pro-natriuretic peptide concentrations in fetuses in the second trimester and in healthy neonates. *Clin Chem Lab Med*. 2006;44(7):834-6.
- 92) Grandone E, Colaizzo D, Martinelli P, *Paladini D*, di Minno G, Margaglione M. Adverse outcome in women with thrombophilia and bilateral uterine artery notches. *Fertil Steril*. 2006 Jul 6.
- 93) D'alto M, Russo MG, Pacileo G, *Paladini D*, Romeo E, Sarubbi B, Cardaropoli D, Ricci C, Calabro R. Left ventricular remodelling in outflow tract obstructive lesions during fetal life. *J Cardiovasc Med (Hagerstown)*. 2006 Oct;7(10):726-730.
- 94) *Paladini D*, Maruotti GM, Sglavo G, Fratellanza G, Quarantelli M, Martinelli P. Massive fetal hemorrhage and fetomaternal alloimmune thrombocytopenia from human platelet antigen 5b incompatibility: an unusual association. *Ultrasound Obstet Gynecol*. 2007 Apr; 29(4):471-4.
- 95) *Paladini D*. Standardisation of onscreen fetal heart orientation prior to storage of Spatio-Temporal Image correlation volume datasets. *Editorial*. *Ultrasound Obstet Gynecol*, 2007; 29:605-11.
- 96) *Paladini D*, Maruotti GM, Sglavo , Penner I, Leone F, D'armiento MR, Martinelli P. Diagnosis of Femoral-hypoplasia unusual facies syndrome in the fetus. *Ultrasound Obstet Gynecol*, 2007
- 97) *Paladini D*, Sglavo G, Penner I, Pastore G, Nappi C. Fetuses with Down syndrome have an enlarged anterior fontanelle in the second trimester of pregnancy. *Ultrasound Obstet Gynecol*. 2007 Nov;30(6):824-9. PubMed PMID: 17803259.
- 98) D'Alto M, Russo MG, *Paladini D*, Di Salvo G, Romeo E, Ricci C, Felicetti M, Tartaglione A, Cardaropoli D, Pacileo G, Sarubbi B, Calabrò R. The challenge of fetal dysrhythmias: echocardiographic diagnosis and clinical management. *J Cardiovasc Med (Hagerstown)*. 2008 Feb;9(2):153-60. PubMed PMID: 18192808.
- 99) *Paladini D*, Volpe P, Sglavo G, Vassallo M, De Robertis V, Marasini M, Russo MG. Transposition of the great arteries in the fetus: assessment of the spatial relationships of the arterial trunks by four-dimensional echocardiography. *Ultrasound Obstet Gynecol*. 2008 Mar;31(3):271-6. PubMed PMID: 18307212.

- 100) Timmerman D, Testa AC, Bourne T, Ameye L, Jurkovic D, Van Holsbeke C, *Paladini D*, Van Calster B, Vergote I, Van Huffel S, Valentin L. Simple ultrasound-based rules for the diagnosis of ovarian cancer. *Ultrasound Obstet Gynecol.* 2008 Jun;31(6):681-90.
- 101) *Paladini D*, Vassallo M, Sglavo G, Nappi C. Struma ovarii associated with hyperthyroidism, elevated CA 125 and pseudo-Meigs syndrome may mimic advanced ovarian cancer. *Ultrasound Obstet Gynecol.* 2008 Aug;32(2):237-8.
- 102) Lee W, Allan L, Carvalho JS, Chaoui R, Copel J, Devore G, Hecher K, Munoz H, Nelson T, *Paladini D*, Yagel S; ISUOG Fetal Echocardiography Task Force. ISUOG consensus statement: what constitutes a fetal echocardiogram? *Ultrasound Obstet Gynecol.* 2008 Aug;32(2):239-42. PubMed PMID: 18663769.
- 103) Savelli L, Testa AC, Timmerman D, *Paladini D*, Ljungberg O, Valentin L. Imaging of gynecological disease (4): clinical and ultrasound characteristics of struma ovarii. *Ultrasound Obstet Gynecol.* 2008 Aug;32(2):210-9.
- 104) Russo MG, *Paladini D*, Pacileo G, Ricci C, Di Salvo G, Felicetti M, Di Pietto L, Tartaglione A, Palladino MT, Santoro G, Caianiello G, Vosa C, Calabrò R. Changing spectrum and outcome of 705 fetal congenital heart disease cases: 12 years, experience in a third-level center. *J Cardiovasc Med (Hagerstown).* 2008 Sep;9(9):910-5.
- 105) *Paladini D*, Vassallo M, Sglavo G, Pastore G, Lapadula C, Nappi C. Normal and abnormal development of the fetal anterior fontanelle: a three-dimensional ultrasound study. *Ultrasound Obstet Gynecol.* 2008 Nov;32(6):755-61. Erratum in: *Ultrasound Obstet Gynecol.* 2009 Mar;33(3):370.
- 106) Di Salvo G, Russo MG, *Paladini D*, Felicetti M, Castaldi B, Tartaglione A, di Pietto L, Ricci C, Morelli C, Pacileo G, Calabrò R. Two-dimensional strain to assess regional left and right ventricular longitudinal function in 100 normal fetuses. *Eur J Echocardiogr.* 2008 Nov;9(6):754-6. Epub 2008 Apr 28.
- 107) *Paladini D*, Sglavo G, Greco E, Nappi C. Cardiac screening by STIC: can sonologists performing the 20-week anomaly scan pick up outflow tract abnormalities by scrolling the A-plane of STIC volumes? *Ultrasound Obstet Gynecol.* 2008 Dec;32(7):865-70.
- 108) Guida M, *Paladini D*, Greco E, Di Spiezio Sardo A, Coppola C, Nappi C. Pregnancy-induced symptomatic pelvic and extra-pelvic cavernous hemangiomas. *Clin Exp Obstet Gynecol.* 2009;36(1):55-7.
- 109) Napolitano R, Maruotti GM, Quarantelli M, Martinelli P, *Paladini D*. Prenatal diagnosis of Seckel Syndrome on 3-dimensional sonography and magnetic resonance imaging. *J Ultrasound Med.* 2009 Mar;28(3):369-74.
- 110) Greco E, Sglavo G, *Paladini D*. Prenatal sonographic diagnosis of Rubinstein-Taybi syndrome. *J Ultrasound Med.* 2009 May;28(5):669-72.
- 111) *Paladini D*. Sonography in obese and overweight pregnant women: clinical, medicolegal and technical issues. *Ultrasound Obstet Gynecol.* 2009 Jun;33(6):720-9. Review.

- 112) *Paladini D, Testa A, Van Holsbeke C, Mancari R, Timmerman D, Valentin L.* Imaging in gynecological disease (5): clinical and ultrasound characteristics in fibroma and fibrothecoma of the ovary. *Ultrasound Obstet Gynecol.* 2009 Aug;34(2):188-95.
- 113) *Paladini D, Volpe P, Sglavo G, Russo MG, De Robertis V, Penner I, Nappi C.* Partial atrioventricular septal defect in the fetus: diagnostic features and associations in a multicenter series of 30 cases. *Ultrasound Obstet Gynecol.* 2009 Sep;34(3):268-73.
- 114) *Maruotti GM, Paladini D, Napolitano R, Mazzarelli LL, Russo T, Quarantelli M, D'Armiento MR, Martinelli P.* Prenatal 2D and 3D ultrasound diagnosis of diprosopus: case report with post-mortem magnetic resonance images (MRI) and review of the literature. *Prenat Diagn.* 2009 Oct;29(10):992-4. Review.
- 115) *Van Holsbeke C, Zhang J, Van Belle V, Paladini D, Guerriero S, Czekierdowski A, Muggah H, Ombelet W, Jurkovic D, Testa AC, Valentin L, Van Huffel S, Bourne T, Timmerman D.* Acoustic streaming cannot discriminate reliably between endometriomas and other types of adnexal lesion: a multicenter study of 633 adnexal masses. *Ultrasound Obstet Gynecol.* 2010 Mar;35(3):349-53.
- 116) *Paladini D.* Fetal micrognathia: almost always an ominous finding. *Ultrasound Obstet Gynecol.* 2010 Apr;35(4):377-84.
- 117) *Van Holsbeke C, Van Calster B, Guerriero S, Savelli L, Paladini D, Lissoni AA, Czekierdowski A, Fischerova D, Zhang J, Mestdagh G, Testa AC, Bourne T, Valentin L, Timmerman D.* Endometriomas: their ultrasound characteristics. *Ultrasound Obstet Gynecol.* 2010 Jun;35(6):730-40.
- 118) *Paladini D, Greco E, Sglavo G, D'Armiento MR, Penner I, Nappi C.* Congenital anomalies of upper extremities: prenatal ultrasound diagnosis, significance, and outcome. *Am J Obstet Gynecol.* 2010 Jun;202(6):596.e1-10. Epub 2010 Feb 20.
- 119) *Van Holsbeke C, Van Belle V, Leone FP, Guerriero S, Paladini D, Melis GB, Gregg S, Fischerova D, De Jonge E, Neven P, Bourne T, Valentin L, Van Huffel S, Timmerman D.* Prospective external validation of the 'ovarian crescent sign' as a single ultrasound parameter to distinguish between benign and malignant adnexal pathology. *Ultrasound Obstet Gynecol.* 2010 Jul;36(1):81-7.
- 120) *Espinoza J, Lee W, Comstock C, Romero R, Yeo L, Rizzo G, Paladini D, Viñals F, Achiron R, Gindes L, Abuhamad A, Sinkovskaya E, Russell E, Yagel S.* Collaborative study on 4-dimensional echocardiography for the diagnosis of fetal heart defects: the COFEHD study. *J Ultrasound Med.* 2010 Nov;29(11):1573-80.
- 121) *D'Alessio F, Mirabelli P, Gorrese M, Scalia G, Gemei M, Mariotti E, Di Noto R, Martinelli P, Fortunato G, Paladini D, Del Vecchio L.* Polychromatic flow cytometry analysis of CD34+ hematopoietic stem cells in cryopreserved early preterm human cord blood samples. *Cytometry A.* 2011 Jan;79(1):14-24.
- 122) *Daemen A, Jurkovic D, Van Holsbeke C, Guerriero S, Testa AC, Czekierdowski A, Fruscio R, Paladini D, Neven P, Rossi A, Bourne T, De Moor B, Timmerman D.* Effect

of cancer prevalence on the use of risk-assessment cut-off levels and the performance of mathematical models to distinguish malignant from benign adnexal masses. *Ultrasound Obstet Gynecol.* 2011 Feb;37(2):226-31.

- 123) *Paladini D, Sglavo G, Masucci A, Pastore G, Nappi C.* The role of 4D ultrasound (STIC + sonoAVC) in the prenatal assessment of atrial morphology cardioplenic syndromes. *Ultrasound Obstet Gynecol.* 2011; 38: 337–343.
  - 124) *Paladini D.* How to identify the thymus in the fetus: the thy-box. *Ultrasound Obstet Gynecol.* 2011 Apr;37(4):488-92..
  - 125) *Paladini D, Sglavo G, Pastore G, Masucci A, D'Armiento MR, Nappi C.* Aberrant Right Subclavian Artery (ARSA). Incidence and correlation with other markers of Down syndrome in 2<sup>nd</sup> trimester fetuses. *Ultrasound Obstet Gynecol* 2012; 39: 191–195.
  - 126) *Paladini D, Quarantelli M, Pastore G, Sorrentino M, Sglavo G, Nappi C.* Abnormal or delayed development of the Area Membranacea Posterior of the brain: the Blake's pouch cyst. Anatomy, ultrasound diagnosis, natural history and outcome in the fetus. *Ultrasound Obstet Gynecol.* 2012; 39: 279–287.
- 

Aggiornato Dicembre 2012